

# \*30737801\*

**Request # 30737801**

**MAR 09, 2011**

**Email (PDF) To: harelson@vvmc.com**

VAIL VALLEY MEDICAL CENTER  
 Library-Shaw Regional Cancer Center  
 322 Beard Creek Road  
 PO Box 2559  
 Edwards, CO 81632

**DOCLINE: Journal Copy**

Title: The Physician and sportsmedicine  
 Title Abbrev: Phys Sportsmed  
 Citation: 2011 Feb;39(1):116-22  
 Article: Acromioclavicular joint injuries: anatomy, diagnos  
 Author: Willimon S;Gaskill T;Millett P  
 NLM Unique ID: 0427461 Verify: PubMed  
 PubMed UI: 21378494  
 ISSN: 0091-3847 (Print)  
 Fill from: **Any format**  
 Publisher: JTE Multimedia, Berwyn, PA :  
 Copyright: Copyright Compliance Law  
 Authorization: Kim Lyons-Mitchell  
 Need By: N/A  
 Maximum Cost: **\$20.00**  
 Patron Name: greta c  
 Library Groups: CCML,FreeShare  
 Phone: 1.970.569-7607  
 Fax: 1.970.569-7613  
 Email: harelson@vvmc.com  
 Alt Delivery: Email(TIFF),Fax,Mail,Web(PDF),Web(TIFF)  
 Comments: **Prefer to work with Free Share program, Prefer fax, or PDF**  
 Routing Reason: Routed to CAUGLD in Serial Routing - cell 1  
 Received: Mar 09, 2011 ( 11:33 AM ET )  
 Lender: Sutter Gould Medical Foundation/ Modesto/ CA  
 USA (CAUGLD)

This material may be protected by copyright law (TITLE 17,U.S. CODE)

**Bill to: COUVYA**

VAIL VALLEY MEDICAL CENTER  
 Library-Shaw Pavilion  
 PO Box 2559  
 Edwards, CO 81632

# Acromioclavicular Joint Injuries: Anatomy, Diagnosis, and Treatment

S. Clifton Willimon, MD; Trevor R. Gaskill, MD; Peter J. Millett, MD, MSc

**Abstract:** Acromioclavicular (AC) joint injuries are common in athletic populations and account for 40% to 50% of shoulder injuries in many contact sports, including lacrosse, hockey, rugby and football. The AC joint is stabilized by static and dynamic restraints, including the coracoclavicular (CC) ligaments. Knowledge of these supporting structures is important when identifying injury and directing treatment. Management of AC injuries should be guided by severity of injury, duration of injury and symptoms, and individual patient factors. These help determine how best to guide management, and whether patients should be treated surgically or nonsurgically. Treatment options for AC injuries continue to expand, and include arthroscopic-assisted anatomic reconstruction of the CC ligaments. The purpose of this article is to review the anatomy, diagnostic methods, and treatment options for AC joint injuries. In addition, the authors' preferred reconstruction technique and outcomes are presented.

**Keywords:** acromioclavicular joint injuries; acromioclavicular separation; graft reconstruction; coracoclavicular ligament reconstruction

S. Clifton Willimon, MD<sup>1</sup>  
Trevor R. Gaskill, MD<sup>1</sup>  
Peter J. Millett, MD, MSc<sup>2</sup>

<sup>1</sup>The Steadman Clinic, Vail, CO;

<sup>2</sup>Steadman Philippon Research  
Institute, Vail, CO

## Introduction

Acromioclavicular (AC) joint injuries are common in athletic populations and account for 40% to 50% of shoulder injuries in many contact sports.<sup>1-3</sup> Bicycling, skiing, lacrosse, hockey, rugby, and football are sports that can result in an AC joint injury.<sup>4</sup> Recent improvements in understanding the biomechanics and anatomy of the AC joint has led to an evolution in treatment techniques. Long-term follow-up studies are becoming available, which will also help guide treatment options.

## Anatomy and Biomechanics

The AC joint is a diarthrodial joint formed by the distal clavicle and medial aspect of the anterior acromion (Figure 1). In the past, this joint was believed to have little motion and served primarily as a link between the glenohumeral joint and the axial skeleton. However, recent research has shown that the biomechanics of this joint are more complex, a finding that is critical in the development of optimal reconstructive techniques.

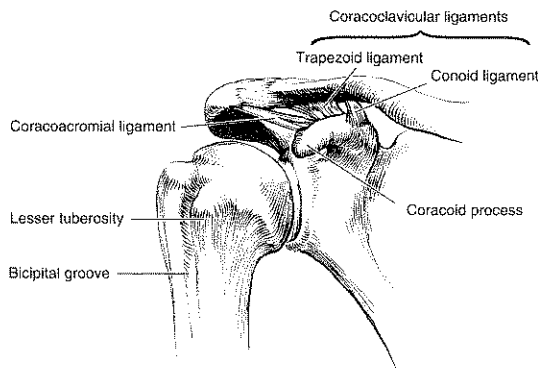
The stability of the AC joint is primarily dependent on the AC and coracoclavicular (CC) ligament complexes. They are responsible for resisting translation and rotation in multiple planes when combined with glenohumeral motion. The normal AC joint is capable of translating 4 to 6 mm in the anterior, posterior, and superior planes under 70-N loads.<sup>5</sup> Other biomechanical evidence indicates that the AC joint accommodates rotary motion of 5° to 8° during scapulothoracic motion and 40° to 45° with shoulder abduction and elevation.<sup>6,7</sup>

The conoid and trapezoid ligaments are  $15.1 \pm 4.1$  mm and  $11.5 \pm 2.2$  mm in length, respectively.<sup>8</sup> Rios et al<sup>9</sup> have shown that the center of the trapezoid is  $25.9 \pm 3.9$  mm and the center of the conoid is  $35.0 \pm 5.9$  mm when measured from the lateral edge of the clavicle medially. In females, the conoid ligament was found to be 0.5 mm more lateral than in males, which is likely due to gender-related differences in clavicle size. The origin of the trapezoid (11.8 mm) is much narrower than the conoid from its origin (25.3 mm). Of note, the conoid ligaments' broad insertion is not routinely centered over the middle of the conoid tuberosity. Rios et al<sup>9</sup> determined that the ratio of each CC ligament insertion to the total clavicle length (17% trapezoid, 31% conoid) is a more accurate guide for CC ligament reconstruction when compared with absolute distance for each CC ligament origin from the distal clavicle, regardless of gender.<sup>9</sup>

### Correspondence:

Peter J. Millett, MD, MSc,  
Steadman Philippon Research Institute,  
181 W. Meadow Dr., Suite 1000,  
Vail, CO 81657.  
E-mail: drmillett@steadmanclinic.net

**Figure 1.** The acromioclavicular joint. The conoid ligament (medial) and trapezoid ligament (lateral) compose the coracoclavicular ligaments.



Reproduced with permission from Simovitch et al.<sup>55</sup>

Currently, research is assessing the structural contributions of the AC and CC ligaments. Harris et al<sup>10</sup> reported that intact CC ligaments demonstrate an ultimate failure load of  $500 \pm 134$  N, stiffness of  $103 \pm 30$  N/mm, and elongation to failure of  $7.7 \pm 1.9$  mm. Studies on ligament sectioning have determined the trapezoid ligament to be the primary restraint to posterior translation, and the inferior AC capsular ligament is the primary restraint to anterior translation.<sup>8</sup> The conoid ligament appears to primarily restrain superior translation and rotation.<sup>5,11</sup> Others have suggested that the posterior and superior AC joint ligaments are primarily responsible for posterior clavicular displacement.<sup>11,12</sup>

The AC ligaments typically fail before the CC ligaments. Therefore, it appears the AC joint ligaments are primarily responsible for resisting small degrees of displacement, whereas the CC ligaments resist larger degrees of displacement. This is important for a general knowledge of AC injury classifications and reconstruction techniques.<sup>11</sup> After complete disruption of the AC ligaments, the CC ligaments become the primary restraint to anteroposterior and vertical clavicular displacement.<sup>13</sup>

## Etiology and Classification

The most common mechanism of AC joint injury is a direct blow to the shoulder with the arm in an adducted position. The acromion is driven inferiorly, which initially results in AC ligament failure. If the displacement is of sufficient magnitude, the CC ligaments also fail, resulting in higher-grade AC joint separation.<sup>5</sup> In 1967, Allman<sup>14</sup> described the original classi-

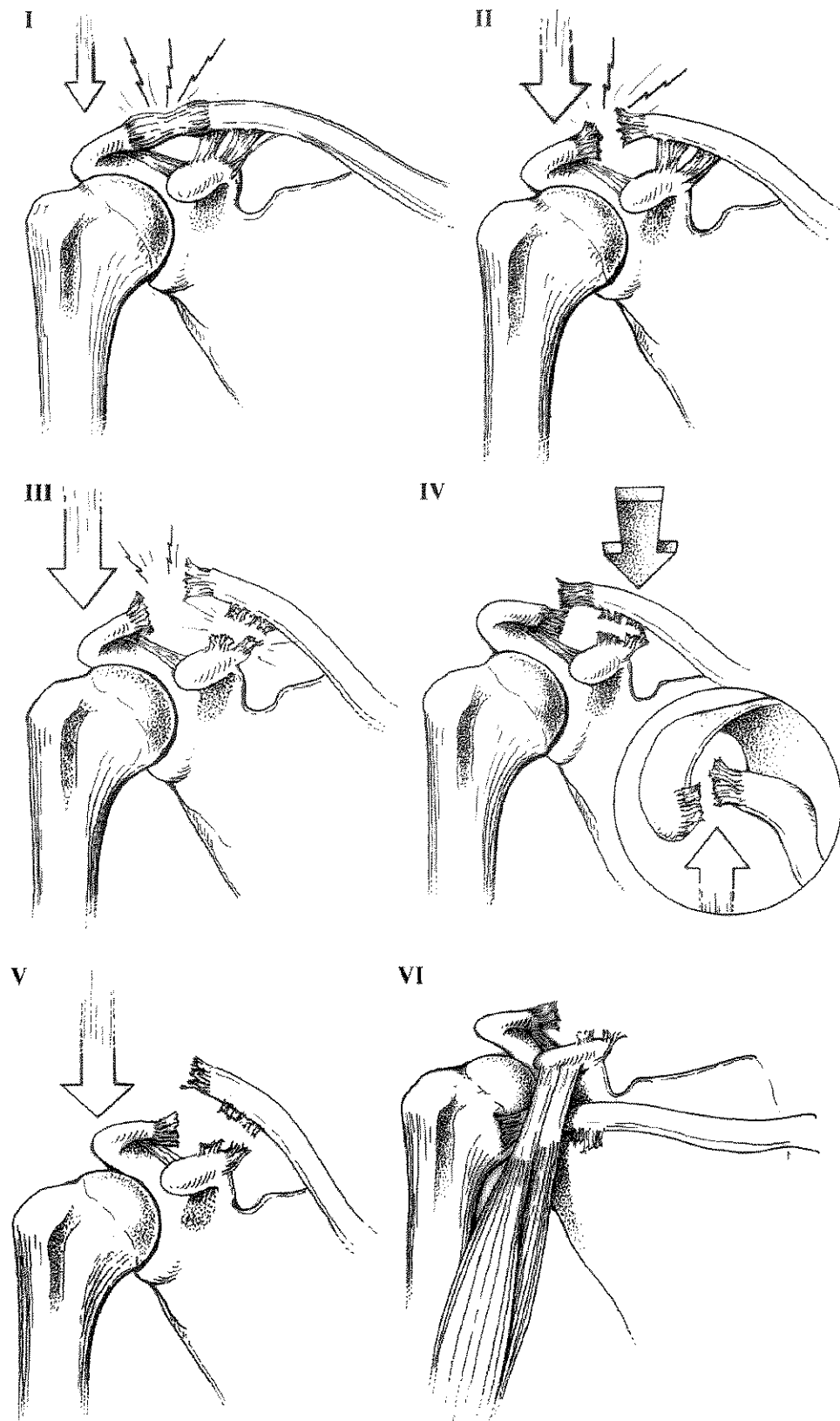
fication of AC joint injuries. In 1984, Rockwood<sup>15</sup> expanded Allman's initial classification of AC joint injuries from 3 to 6 types (Figure 2).<sup>15</sup> Type I injuries represent an AC joint ligament strain with no apparent changes, as seen by radiographs. A type II injury occurs when the AC joint ligaments are disrupted, but the CC ligaments remain intact. Radiographs may identify a slight depression of the acromion relative to the clavicle. When both the AC joint ligaments and CC ligaments are disrupted, a type III ligament injury is present. In this case, the AC joint is unrestrained and may displace up to 100% of the CC distance, as seen radiographically. Type III injuries are passively reducible on physical examination. In comparison, type V injuries are not completely reducible because the distal clavicle has button-holed through the trapezial fascia, which is interposed and inhibits reduction. Types IV to VI injuries also represent complete disruption of both ligament complexes and are defined by the direction of displacement of the clavicle. Posterior superior displacement  $> 100\%$  of the CC distance and inferior displacement characterize types IV, V, and VI injuries.<sup>15</sup>

## Clinical Presentation

Physical examination may reveal abrasions of the shoulder and prominence of the distal clavicle as a result of inferior displacement of the scapula. Palpation of the AC joint will reveal tenderness, and shoulder range of motion is typically limited by pain. Motions that result in AC joint loading, such as cross-body adduction, may exacerbate symptoms. A thorough upper extremity evaluation should be performed to identify additional injuries. Intra-articular injuries (eg, rotator cuff and labral tears) and shoulder girdle and thorax injuries (eg, coracoid fracture, rib fractures, pneumothorax, sternoclavicular joint injuries, floating shoulders, brachial plexus injuries, and scapulothoracic dissociations) have been reported.<sup>16-20</sup>

Standard anteroposterior, lateral, and axillary radiographs should be obtained in any patient with a suspected shoulder injury. If an AC joint injury is suspected, a Zanca view is often helpful and is obtained by tilting the radiograph beam  $10^\circ$  to  $15^\circ$  cephalad as compared with a standard shoulder radiograph.<sup>21</sup> This results in a clear view of the AC joint without being superimposed over other osseous shoulder structures. The axillary view is useful to visualize the degree of posterior displacement of the clavicle. Weighted stress views are not used because they provide little additional information and are associated with higher costs and patient discomfort.

Figure 2. Classification of acromioclavicular joint injuries.



Reproduced with permission from Ponce et al.<sup>56</sup>

## Treatment

There is controversy regarding optimal treatment of AC joint injuries. Most authors support nonoperative treatment of types I and II injuries and recommend operative reduction and fixation for types IV to VI injuries. However, there is debate regarding treatment of type III injuries. Nonoperative treatment typically consists of brief immobilization (1 week), cryotherapy, and early range of motion. Satisfactory outcomes are often reported with this treatment method.<sup>22-24</sup> More recently, however, some evidence has indicated that long-term outcomes may not be as optimal as initially reported. For example, Mikek<sup>25</sup> reported that nearly 50% of patients who received nonsurgical treatment for grades II and III reported some impairment in shoulder function at long-term follow-up, but no patients felt that the impairment required surgical intervention.

Optimal treatment of type III AC separations is debated. There is evidence supporting both operative and nonoperative management.<sup>26-29</sup> In a prospective study, 16 (80%) of 20 patients with a type III injury who were treated nonsurgically demonstrated no objective difference in shoulder range of motion or rotational strength. However, 4 (20%) patients reported that their long-term function was suboptimal.<sup>30</sup> Others have suggested that there is no difference in strength among patients treated nonoperatively and operatively at 2-year follow-up.<sup>28</sup> Because most literature has demonstrated good outcomes with nonoperative treatment of type III injuries, most authors consider nonoperative management to be the preferred initial treatment of type III injuries. Surgical intervention is offered to those who continue to experience pain, clavicular instability, or decreased strength.

In contrast, several authors have reported that patients who underwent early reconstruction had significantly better outcomes when compared with those who failed initial nonoperative care and underwent reconstruction > 3 months after injury.<sup>31,32</sup> For this reason, early surgical intervention is occasionally considered for high-level athletes, laborers, and overhead athletes.<sup>31,33,34</sup> These reports emphasize the need for additional research to determine which patients with type III injuries would benefit from early surgical intervention.

## Surgical Techniques

There are many surgical techniques available to reconstruct the separated AC joint. These include CC fixation, dynamic muscle or ligament transfer, and CC ligament reconstruction. It is well known that considerable motion occurs at the AC joint.

This motion is likely responsible for high failure rates reported after rigid fixation techniques (eg, CC screws, Kirschner wires, Steinman pins, or hook plates).<sup>35-38</sup> As a result, use of these techniques has declined in clinical practice.

In 1972, Weaver and Dunn<sup>39</sup> described a reconstruction technique consisting of distal clavicle excision and transfer of the coracoacromial (CA) ligament to the distal clavicle. Since this original description, numerous modifications have been made, including harvest of the CA ligament with an acromial bone block,<sup>40</sup> suture augmentation,<sup>41,42</sup> autograft augmentation,<sup>43</sup> and arthroscopic techniques.<sup>44,45</sup>

Many clinical studies have reported good clinical results with the modified Weaver-Dunn reconstruction.<sup>33,39,46,47</sup> However, several clinical studies have described residual AC subluxation or dislocation after CA ligament transfer.<sup>31,48,49</sup> In addition, biomechanical studies have revealed that a CA ligament transfer restores only 25% to 50% of the native CC ligament strength.<sup>43,50</sup> These shortcomings, in the context of an improved biomechanical understanding of AC joint stability, have driven the development of anatomic reconstruction techniques.

Mazzocca et al<sup>51</sup> compared anatomic CC with modified Weaver-Dunn reconstructions in a cadaveric model. The authors demonstrated decreased translation and laxity after the anatomic reconstruction. Others have confirmed this finding and suggest that an anatomic reconstruction yields a more robust reconstruction compared with other techniques.<sup>10,52</sup>

## Authors' Preferred Surgical Technique

The authors prefer an arthroscopic-assisted anatomic reconstruction of the CC ligaments using a tibialis tendon allograft. This reconstruction technique allows for anatomical restoration of CC ligaments while providing a biomechanically superior construct, as discussed previously. The patient is placed in a modified beach-chair position and the injured extremity is prepped free. Standard anterior and posterior portals are established and any intra-articular injuries are addressed. A transarticular approach is used to expose the coracoid process through the rotator interval. The anterior joint capsule is opened using a radiofrequency ablator, and the coracoid process is identified. A 70° arthroscope is frequently used to improve visualization of the coracoid. An accessory inferolateral portal is also made to aid coracoid exposure and facilitate graft passage. This portal is placed inferior to the anterolateral border

of the acromion, roughly at the level of the coracoid process. The coracoid is skeletonized while preserving the conjoined tendon and pectoralis minor attachments using a radiofrequency device, small elevator, and oscillating shaver. Care must be taken medial to the coracoid to avoid injury to the brachial plexus.

A 4-cm incision is made perpendicular to the clavicle approximately 3.5 cm medial to the lateral extent of the clavicle. This places the incision in a position to facilitate distal clavicle resection and CA ligament reconstruction. The AC joint capsule and superior clavicular fascia is incised to bone parallel to the clavicle. This fascial layer is elevated as a single flap for later imbrication over the reconstruction to provide additional stability.

The distal clavicle is lifted from the incision using an elevator, and the distal 1 cm is removed using an oscillating saw. It is critical to release the deltoid fascia from the anterior clavicle to facilitate eventual graft passage. Next, a switching stick is placed from the clavicular incision along the medial border of the coracoid. Standard dilators are used to ensure sufficient space for graft passage. Prior to removal of the final cannulated dilator, a fiber stick is advanced through the dilator and retrieved with a grasper from the inferolateral portal. Passing sutures are shuttled into place.

Two tunnels are drilled in a distal clavicle corresponding with the anatomic locations of the conoid and trapezoid ligament insertions. The size of the tunnels is based on graft size, but is typically 6 mm. A 6-mm tibialis allograft is passed through the medial tunnel and, along with a braided 9-strand PDS cable, is passed under the coracoid and through the inferolateral portal using the previously placed passing suture. The graft and PDS cable are then shuttled under deltoid into the clavicular incision using an additional shuttle suture. The tibialis allograft is passed through the lateral clavicular tunnel. The clavicle is reduced and the allograft tendon tensioned prior to placing two 5.5-mm polyetheretherketone (PEEK™) interference screws to secure the graft. The free ends of the graft are sewn to each other for added security.

The PDS cable is then tied over the clavicle to function as an internal splint while the allograft is healing. It is important to tension the graft prior to tying the PDS cable to ensure that the clavicle does not elevate as the PDS cable absorbs. After copious irrigation, the fascial layer overlying the clavicle is imbricated to reinforce the repair. The arthroscopic portals and superior incisions are routinely closed.

## Rehabilitation

The preferred rehabilitation following arthroscopic-assisted anatomic reconstruction of the CC ligaments using a tibialis tendon allograft uses the following regimen. A sling is worn for protection for the first 4 to 6 weeks, and full supine passive range of motion begins immediately. Active motion and strengthening begins after the first 4 to 6 weeks and is advanced as the patient tolerates. Return to sport typically occurs 4 to 6 months after surgery.

## Surgical Outcome

Many investigators have published outcomes on different reconstruction techniques. In 1972, Weaver and Dunn<sup>39</sup> employed CA ligament transfer when treating 12 acute and 3 chronic cases of AC ligament injury (Allman type III injury), in which 11 patients reported “good” outcomes, 3 reported “fair” outcomes, and 1 reported a “poor” outcome. Loss of reduction is the most common source of failure in the modified Weaver-Dunn technique, which occurs in almost one-fourth of patients in some series.<sup>31,39,48</sup> Early reports suggest that anatomic reconstruction techniques using tendon grafts have lower rates of loss of reduction, which is likely due to improved fixation and increased strength of tendon graft relative to the CA ligament.<sup>53</sup> Tauber et al<sup>49</sup> recently compared a single surgeon’s consecutive case series of 12 patients treated with a modified Weaver-Dunn procedure followed by 12 patients treated with a reconstruction technique using semitendinosus autograft.<sup>49</sup> Results showed superior functional and radiographic results in patients treated with tendon graft reconstruction compared with those treated with a modified Weaver-Dunn technique.

In a presentation at the 2010 Annual Meeting of the American Orthopedic Society for Sports Medicine (Providence, RI), Register et al<sup>54</sup> reported their results of 20 shoulders (in 19 consecutive athletes; 3 women, 16 men) that were treated with an anatomic CC ligament reconstruction, as described previously.

Average follow-up was 1.9 years (range, 1.1–3.1 years). According to the Rockwood classification, 7 patients had chronic symptomatic type III injury, 2 had acute type IV injury, and 11 had type V injury. The average age of patients in this series was 45.8 years (range, 24–66 years). Tibialis anterior allograft was used for 18 procedures, and tibialis posterior allograft was used in 1 patient to reconstruct the CA ligaments. The reconstruction was performed using an open technique in the first 14 patients and an arthroscopic technique in the

final 5 patients. The ultimate repair was identical despite use of an open or arthroscopic surgical technique.

American Shoulder and Elbow Surgeons scores improved from 67 preoperatively (range, 37–97) to 95 postoperatively (range, 88–100). Pain according to visual analog scale decreased from 2.2 to 0.25 after surgical intervention. Each measure represents a significant improvement from patients' preoperative status ( $P < 0.05$ ). One patient required revision AC reconstruction at 13 months postoperatively because of a sports-related injury after a full return to activities. Another patient required arthroscopic lysis of adhesions and manipulation under anesthesia 3.7 months postoperatively due to arthrofibrosis. Overall, patients were satisfied with the procedure, averaging 9 points out of a maximum of 10 (range, 5–10). Patients also reported significantly less pain while performing activities of daily living, work and recreational activities, and sleep ( $P < 0.05$ ).

## Conclusion

Acromioclavicular joint injuries are common, and types I and II injuries can typically be treated without surgery. Surgery may be indicated in patients with high-grade separations and in those who fail initial nonoperative management due to weakness, discomfort, or cosmetic concerns. Many surgical techniques are available to manage patients, though recent biomechanical and clinical studies support anatomic CA reconstruction specifically as a more robust reconstruction. Arthroscopic-assisted anatomical CC ligament reconstruction with tibialis tendon allograft has resulted in excellent patient outcomes. This technique is the authors' preferred reconstruction technique, given recent biomechanical and anatomical studies.

## Conflict of Interest Statement

S. Clifton Willimon, MD and Trevor R. Gaskill, MD disclose potential conflicts of interest with Steadman Philippon Research Institute (SPRI). Peter J. Millett, MD, MSc discloses conflicts of interest with Arthrex, Inc., ArthroCare Corp., Game Ready, SPRI, and VuMedi. The authors received no financial support in the preparation of this article.

## References

1. Agel J, Dompier TP, Dick R, Marshall SW. Descriptive epidemiology of collegiate men's ice hockey injuries: National Collegiate Athletic Association Injury Surveillance System, 1988–1989 through 2003–2004. *J Athl Train.* 2007;42(2):241–248.
2. Kaplan LD, Flanigan DC, Norwig J, Jost P, Bradley J. Prevalence and variance of shoulder injuries in elite collegiate football players. *Am J Sports Med.* 2005;33(8):1142–1146.
3. Dick R, Romani WA, Agel J, Case JG, Marshall SW. Descriptive epidemiology of collegiate men's lacrosse injuries: National Collegiate Athletic Association Injury Surveillance System, 1988–1989 through 2003–2004. *J Athl Train.* 2007;42(2):255–261.
4. Millett PJ, Braun S, Gobeze R, Pacheco IH. Acromioclavicular joint reconstruction with coracoacromial ligament transfer using the docking technique. *BMC Musculoskelet Disord.* 2009;10:6.
5. Debski RE, Parsons IM 3rd, Fenwick J, Vangura A. Ligament mechanics during three degree-of-freedom motion at the acromioclavicular joint. *Ann Biomed Eng.* 2000;28(6):612–618.
6. Kennedy JC. Complete dislocation of the acromioclavicular joint: 14 years later. *J Trauma.* 1968;8(3):311–318.
7. Flatow EL. The biomechanics of the acromioclavicular, sternoclavicular, and scapulothoracic joints. *Instr Course Lect.* 1993;42:237–245.
8. Lee KW, Debski RE, Chen CH, Woo SL, Fu FH. Functional evaluation of the ligaments at the acromioclavicular joint during anteroposterior and superoinferior translation. *Am J Sports Med.* 1997;25(6):858–862.
9. Rios CG, Arciero RA, Mazzocca AD. Anatomy of the clavicle and coracoid process for reconstruction of the coracoclavicular ligaments. *Am J Sports Med.* 2007;35(5):811–817.
10. Harris RI, Wallace AL, Harper GD, Goldberg JA, Sonnabend DH, Walsh WR. Structural properties of the intact and the reconstructed coracoclavicular ligament complex. *Am J Sports Med.* 2000;28(1):103–108.
11. Fukuda K, Craig EV, An KN, Cofield RH, Chao EY. Biomechanical study of the ligamentous system of the acromioclavicular joint. *J Bone Joint Surg Am.* 1986;68(3):434–440.
12. Klimkiewicz JJ, Williams GR, Sher JS, Karduna A, Des Jardins J, Iannotti JP. The acromioclavicular capsule as a restraint to posterior translation of the clavicle: a biomechanical analysis. *J Shoulder Elbow Surg.* 1999;8(2):119–124.
13. Debski RE, Parsons IM 4th, Woo SL, Fu FH. Effect of capsular injury on acromioclavicular joint mechanics. *J Bone Joint Surg Am.* 2001;83-A:1344–1351.
14. Allman FL Jr. Fractures and ligamentous injuries of the clavicle and its articulation. *J Bone Joint Surg Am.* 1967;49(4):774–784.
15. Rockwood C Jr, ed. *Injuries to the Acromioclavicular Joint.* Philadelphia, PA: Saunders; 1984.
16. Egol KA, Connor PM, Karunakar MA, Sims SH, Bosse MJ, Kellam JF. The floating shoulder: clinical and functional results. *J Bone Joint Surg Am.* 2001;83-A(8):1188–1194.
17. Ebraheim NA, An HS, Jackson WT, et al. Scapulothoracic dissociation. *J Bone Joint Surg Am.* 1988;70(3):428–432.
18. Wilson KM, Colwill JC. Combined acromioclavicular dislocation with coracoclavicular ligament disruption and coracoid process fracture. *Am J Sports Med.* 1989;17(5):697–698.
19. Tischer T, Salzmann GM, El-Azab H, Vogt S, Imhoff AB. Incidence of associated injuries with acute acromioclavicular joint dislocations types III through V. *Am J Sports Med.* 2009;37(1):136–139.
20. Pauly S, Gerhardt C, Haas NP, Scheibel M. Prevalence of concomitant intraarticular lesions in patients treated operatively for high-grade acromioclavicular joint separations. *Knee Surg Sports Traumatol Arthrosc.* 2009;17(5):513–517.
21. Zanca P. Shoulder pain: involvement of the acromioclavicular joint. (Analysis of 1,000 cases). *Am J Roentgenol Radium Ther Nucl Med.* 1971;112(3):493–506.
22. Bergfeld JA, Andrich JT, Clancy WG. Evaluation of the acromioclavicular joint following first- and second-degree sprains. *Am J Sports Med.* 1978;6(4):153–159.
23. Glick JM, Milburn LJ, Haggerty JF, Nishimoto D. Dislocated acromioclavicular joint: follow-up study of 35 unreduced acromioclavicular dislocations. *Am J Sports Med.* 1977;5(6):264–270.

24. Bjerneld H, Hovelius L, Thorling J. Acromio-clavicular separations treated conservatively. A 5-year follow-up study. *Acta Orthop Scand*. 1983;54(5):743-745.
25. Mikek M. Long-term shoulder function after type I and II acromioclavicular joint disruption. *Am J Sports Med*. 2008;36(11):2147-2150.
26. Wojtys EM, Nelson G. Conservative treatment of Grade III acromioclavicular dislocations. *Clin Orthop Relat Res*. 1991;268:112-119.
27. Walsh WM, Peterson DA, Shelton G, Neumann RD. Shoulder strength following acromioclavicular injury. *Am J Sports Med*. 1985;13(3):153-158.
28. Tibone J, Sellers R, Tonino P. Strength testing after third-degree acromioclavicular dislocations. *Am J Sports Med*. 1992;20(3):328-331.
29. MacDonald PB, Alexander MJ, Frejuk J, Johnson GE. Comprehensive functional analysis of shoulders following complete acromioclavicular separation. *Am J Sports Med*. 1988;16(5):475-480.
30. Schlegel TF, Burks RT, Marcus RL, Dunn HK. A prospective evaluation of untreated acute grade III acromioclavicular separations. *Am J Sports Med*. 2001;29(6):699-703.
31. Weinstein DM, McCann PD, McIlveen SJ, Flatow EL, Bigliani LU. Surgical treatment of complete acromioclavicular dislocations. *Am J Sports Med*. 1995;23(3):324-331.
32. Rolf O, Hann von Weyhern A, Ewers A, Boehm TD, Gohlke F. Acromioclavicular dislocation Rockwood III-V: results of early versus delayed surgical treatment. *Arch Orthop Trauma Surg*. 2008;128(10):1153-1157.
33. Larsen E, Bjerg-Nielsen A, Christensen P. Conservative or surgical treatment of acromioclavicular dislocation. A prospective, controlled, randomized study. *J Bone Joint Surg Am*. 1986;68(4):552-555.
34. Bannister GC, Wallace WA, Stableforth PG, Hutson MA. The management of acute acromioclavicular dislocation. A randomised prospective controlled trial. *J Bone Joint Surg Br*. 1989;71(5):848-850.
35. Norrell H Jr, Llewellyn RC. Migration of a threaded steinmann pin from an acromioclavicular joint into the spinal canal. A case report. *J Bone Joint Surg Am*. 1965;47:1024-1026.
36. Sethi GK, Scott SM. Subclavian artery laceration due to migration of a Hagie pin. *Surgery*. 1976;80(5):644-646.
37. Sim E, Schwarz N, Höcker K, Berzlanovich A. Repair of complete acromioclavicular separations using the acromioclavicular-hook plate. *Clin Orthop Relat Res*. 1995;314:134-142.
38. Skjeldal S, Lundblad R, Dullerud R. Coracoid process transfer for acromioclavicular dislocation. *Acta Orthop Scand*. 1988;59(2):180-182.
39. Weaver JK, Dunn HK. Treatment of acromioclavicular injuries, especially complete acromioclavicular separation. *J Bone Joint Surg Am*. 1972;54(6):1187-1194.
40. Kawabe N, Watanabe R, Sato M. Treatment of complete acromioclavicular separation by coracoacromial ligament transfer. *Clin Orthop Relat Res*. 1984;185:222-227.
41. Breslow MJ, Jazrawi LM, Bernstein AD, Kummer FJ, Rokito AS. Treatment of acromioclavicular joint separation: suture or suture anchors? *J Shoulder Elbow Surg*. 2002;11(3):225-229.
42. Deshmukh AV, Wilson DR, Zilberfarb JL, Perlmutter GS. Stability of acromioclavicular joint reconstruction: biomechanical testing of various surgical techniques in a cadaveric model. *Am J Sports Med*. 2004;32(6):1492-1498.
43. Grutter PW, Petersen SA. Anatomical acromioclavicular ligament reconstruction: a biomechanical comparison of reconstructive techniques of the acromioclavicular joint. *Am J Sports Med*. 2005;33(11):1723-1728.
44. Lafosse L, Baier GP, Leuzinger J. Arthroscopic treatment of acute and chronic acromioclavicular joint dislocation. *Arthroscopy*. 2005;21(8):1017.
45. Wolf EM, Pennington WT. Arthroscopic reconstruction for acromioclavicular joint dislocation. *Arthroscopy*. 2001;17(5):558-563.
46. Shoji H, Roth C, Chuinard R. Bone block transfer of coracoacromial ligament in acromioclavicular injury. *Clin Orthop Relat Res*. 1986;208:272-277.
47. Kumar S, Penematsa SR, Selvan T. Surgical reconstruction for chronic painful acromioclavicular joint dislocations. *Arch Orthop Trauma Surg*. 2007;127(6):481-484.
48. Tienen TG, Oyen JF, Eggen PJ. A modified technique of reconstruction for complete acromioclavicular dislocation: a prospective study. *Am J Sports Med*. 2003;31(5):655-659.
49. Tauber M, Gordon K, Koller H, Fox M, Resch H. Semitendinosus tendon graft versus a modified Weaver-Dunn procedure for acromioclavicular joint reconstruction in chronic cases: a prospective comparative study. *Am J Sports Med*. 2009;37(1):181-190.
50. Lee SJ, Nicholas SJ, Akizuki KH, McHugh MP, Kremenic IJ, Ben-Avi S. Reconstruction of the coracoclavicular ligaments with tendon grafts: a comparative biomechanical study. *Am J Sports Med*. 2003;31(5):648-655.
51. Mazzocca AD, Santangelo SA, Johnson ST, Rios CG, Dumonski ML, Arciero RA. A biomechanical evaluation of an anatomical coracoclavicular ligament reconstruction. *Am J Sports Med*. 2006;34(2):236-246.
52. Michlitsch MG, Adamson GJ, Pink M, Estess A, Shankwiler JA, Lee TQ. Biomechanical comparison of a modified Weaver-Dunn and a free-tissue graft reconstruction of the acromioclavicular joint complex. *Am J Sports Med*. 2010;38(6):1196-1203.
53. Carofino BC, Mazzocca AD. The anatomic coracoclavicular ligament reconstruction: surgical technique and indications. *J Shoulder Elbow Surg*. 2010;19(2 suppl):37-46.
54. Register BC, Horan MP, Kunkel RP, Millett PJ. Anatomic acromioclavicular reconstruction with tibialis anterior tendon allograft: technique and preliminary outcomes. Presented at the American Orthopedic Society for Sports Medicine Annual Meeting; Providence, RI; 2010.
55. Simovitch R, Sanders B, Ozbaydar M, Lavery K, Warner JJ. Acromioclavicular joint injuries: diagnosis and management. *J Am Acad Orthop Surg*. 2009;17(4):207-219.
56. Ponce BA, Millett PJ, Warner JJ. Acromioclavicular joint instability—reconstruction indications and techniques. *Oper Technique Sports Med*. 2004;V12(1):35-42.